

題號： 172

國立臺灣大學 108 學年度碩士班招生考試試題

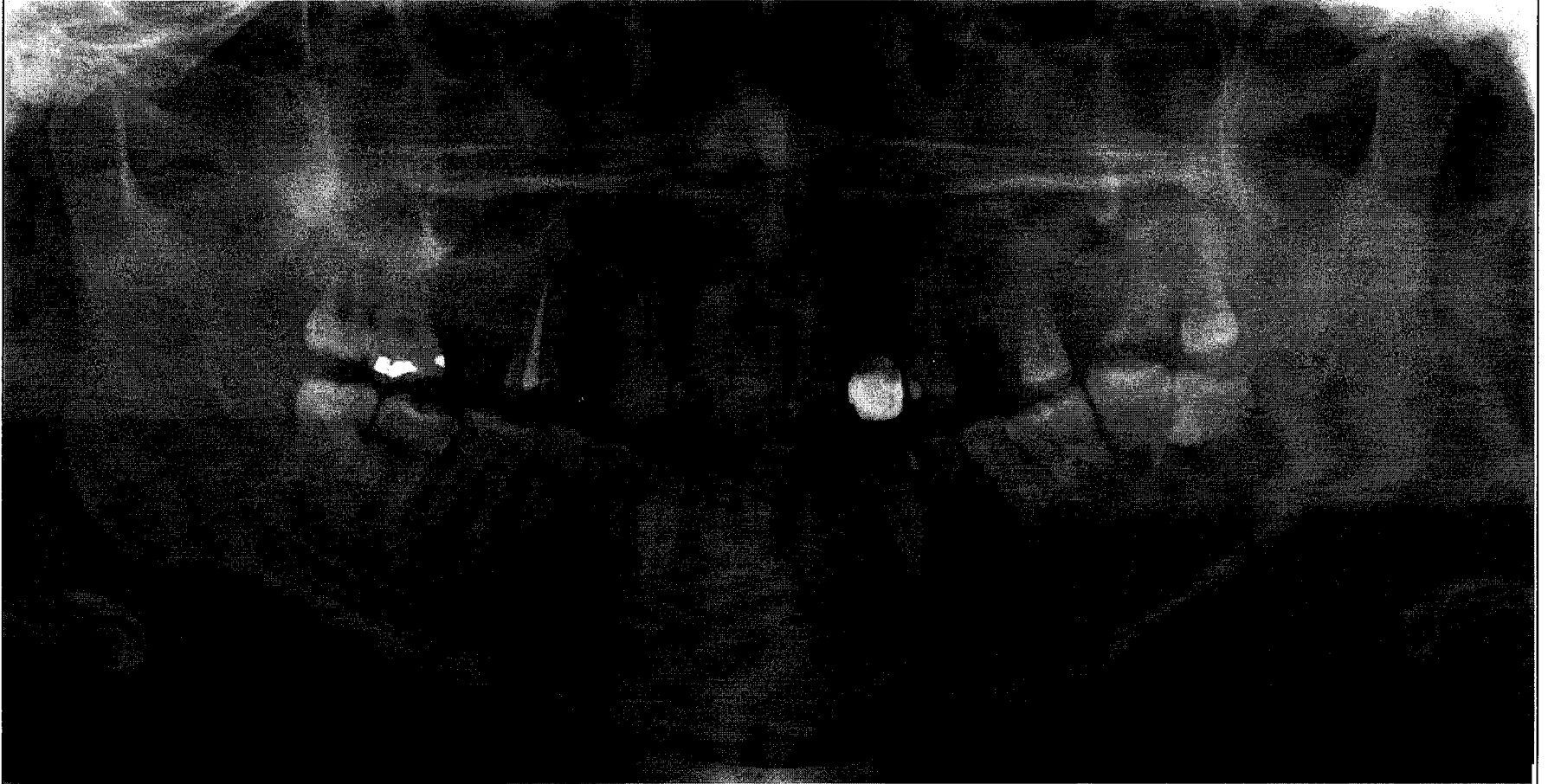
科目： 口腔病理學

題號：172

節次： 2

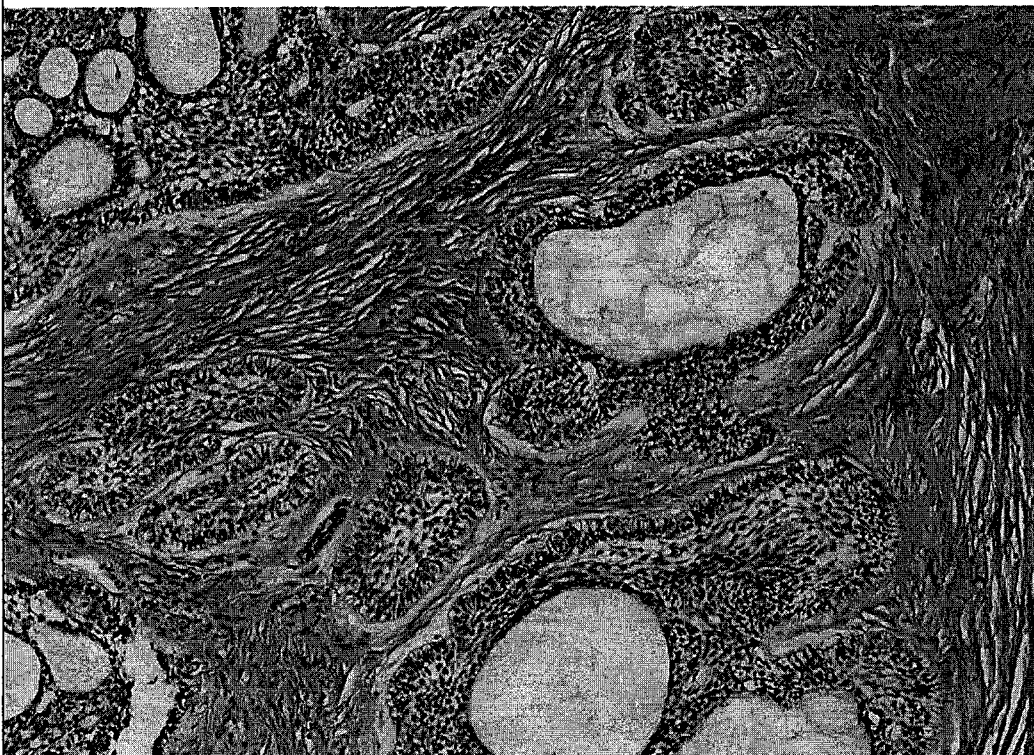
共 8 頁之第 1 頁

1. A 26 year old female presented with a painless swelling in the left mandibular area for 3 years. Clinically the mucosa overlying the left mandibular area was intact. A panoramic radiograph was taken and shown as the image below. (10 分)



What is your differential diagnosis based on radiographic findings?

A biopsy reveals this histology.

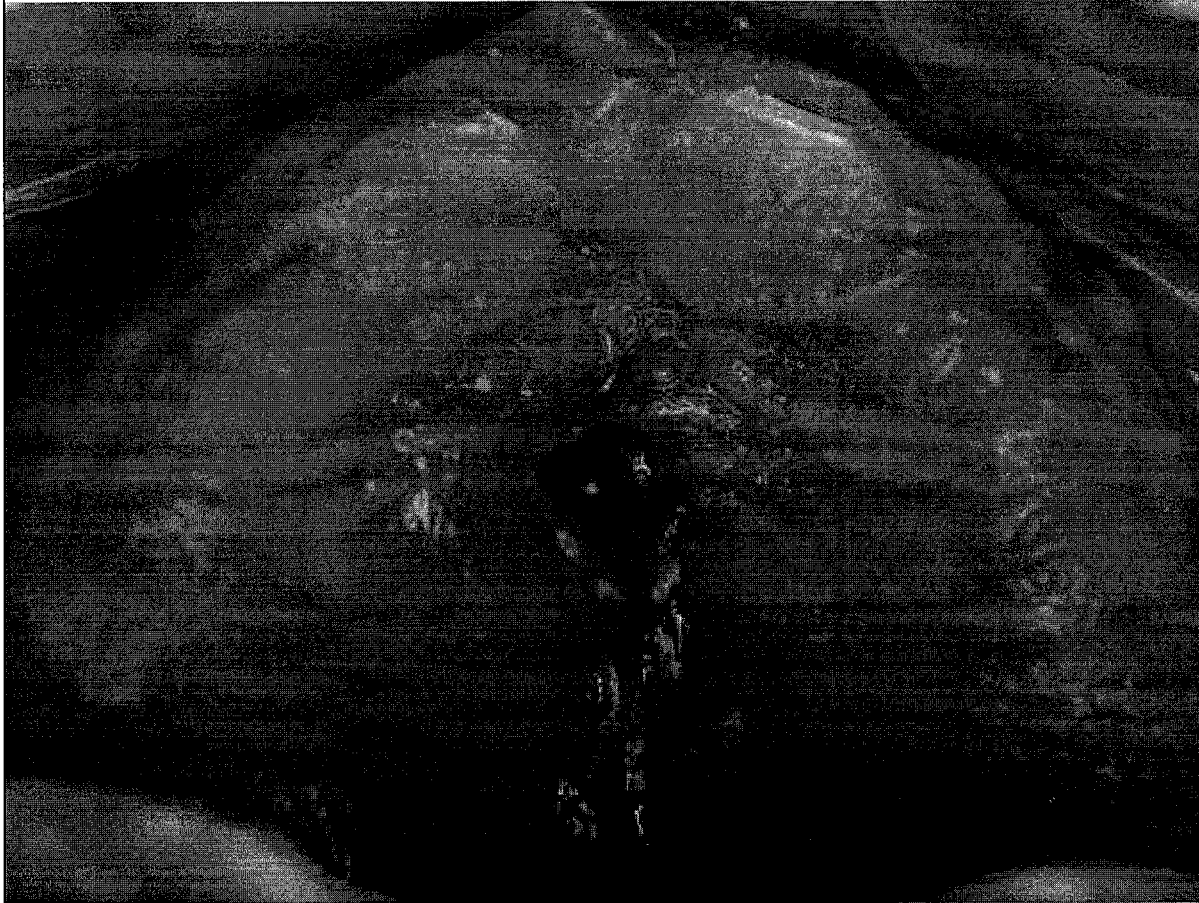


Your final diagnosis is:

What characteristic features let you make this diagnosis?

見背面

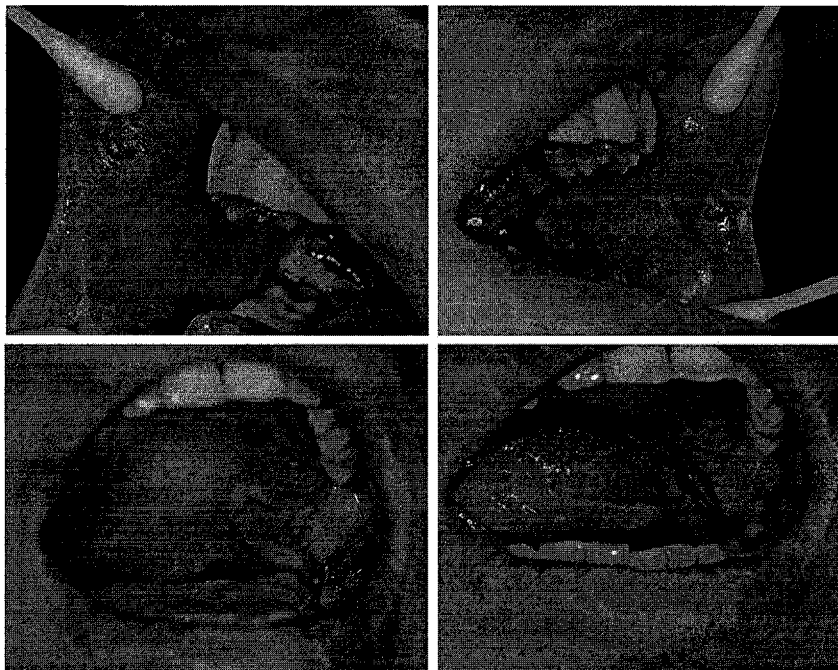
2. A 68 year old male presented with a painful lesion in the midline anterior hard palate. Clinically the mucosa overlying the hard palate was ulcerative and showed a perforation as the clinical image below. (10 分)



What is your differential diagnosis?

How do you work up this case and what is your treatment plan?

3. A 49 year old male presented with multiple painful oral ulcers in the oral cavity. Clinically the ulcerations were involved bilateral buccal mucosa, soft palate and lateral borders and ventral tongue as the clinical image below. (10 分)

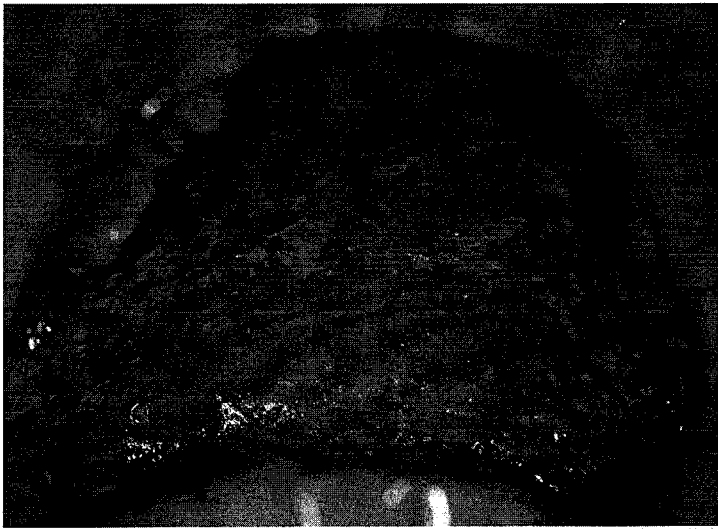


接次頁

What is your differential diagnosis?

How do you work up this case and what is your treatment plan?

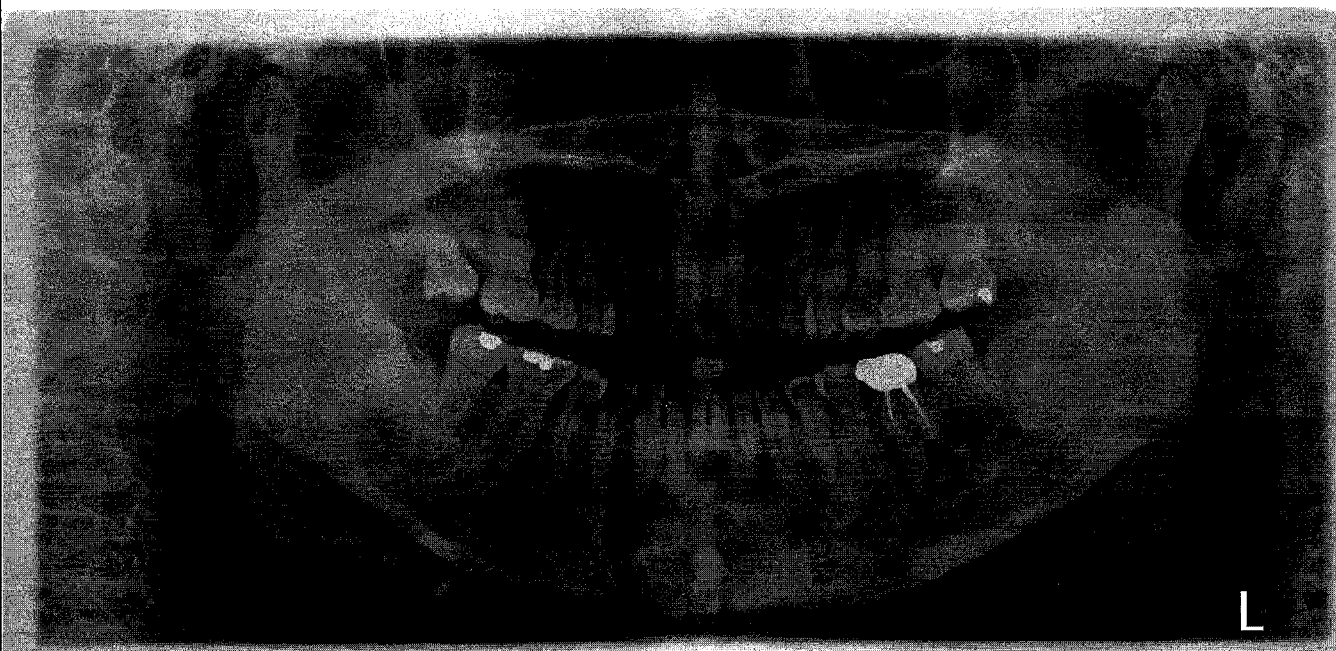4. A 29 year old male complained of soreness at his whole mouth. Clinically the lesions were involved all oral mucosa, including bilateral buccal mucosa, palate and tongue. The clinical image from palate was shown below. (10 分)



What is your differential diagnosis?

How do you work up this case and what is your treatment plan?

5. A 48 year old female complained of tooth 17 hypermobility and went to local dental clinic for evaluation. A panoramic radiograph was taken and shown as the image below. Due to the lesions in the mandible, the dentist referred the patient to you for further evaluation and treatment. (10 分)

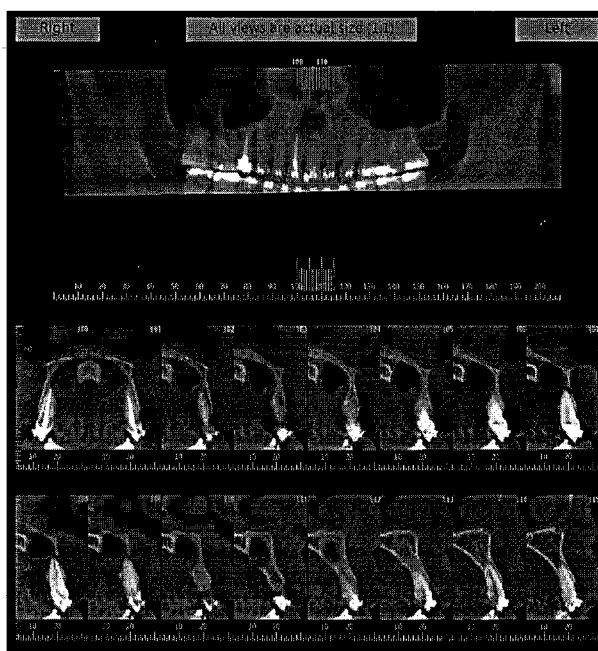
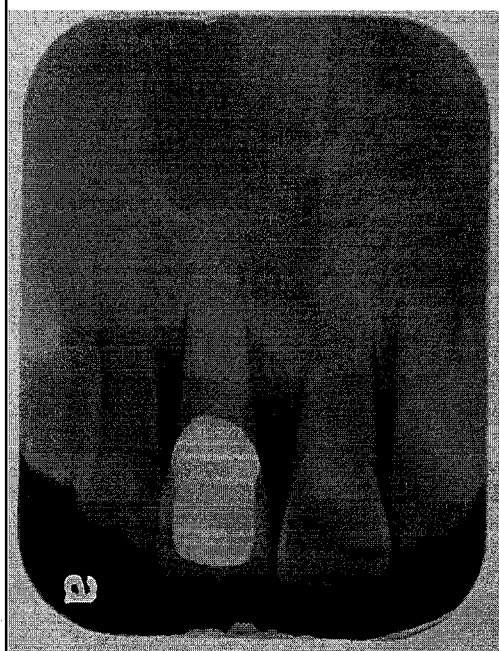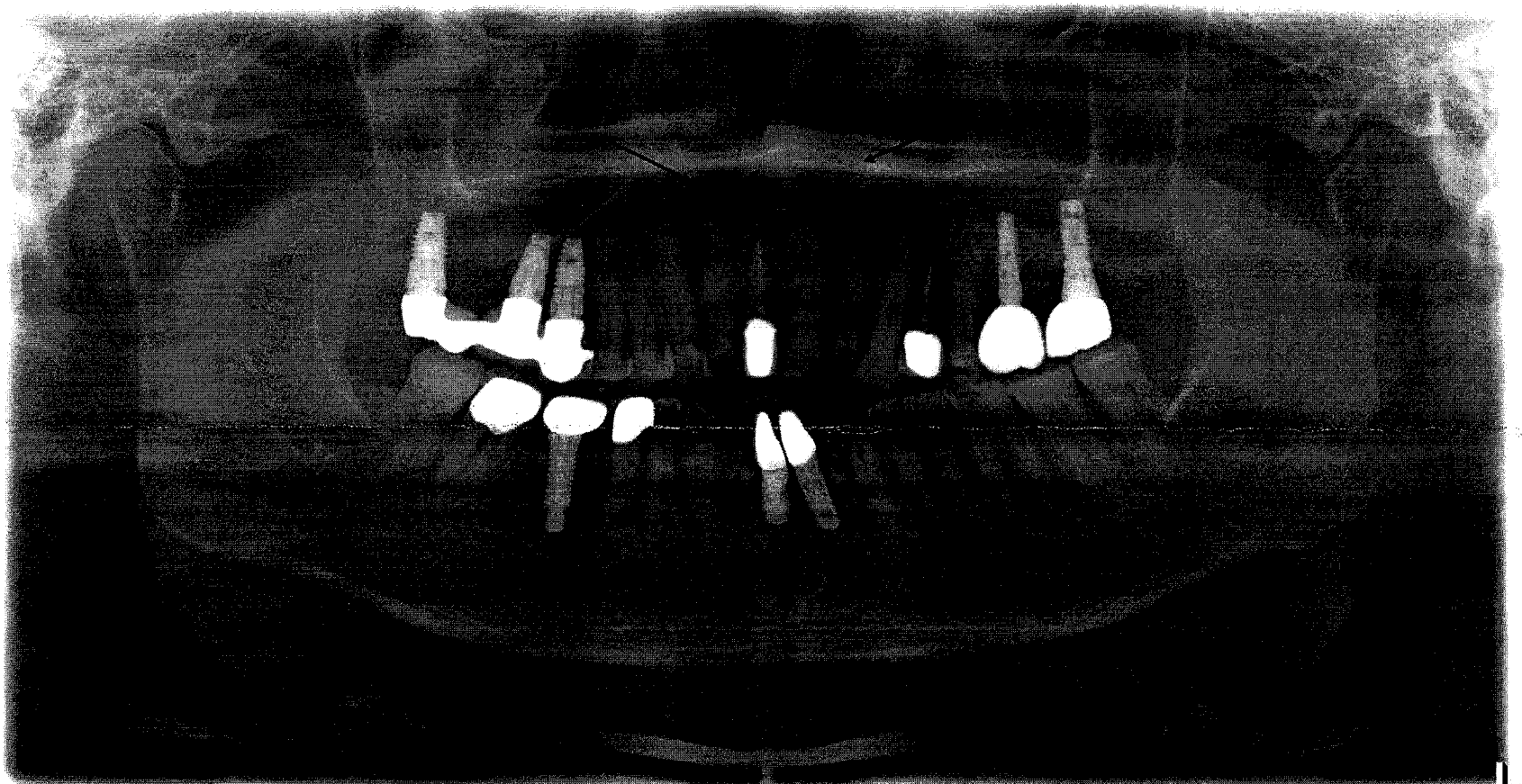


見背面

What is your differential diagnosis?

How do you work up this case and what is your treatment plan?

6. A 31 year old male complained of easily bleeding when brushing and went to local dental clinic for evaluation. A panoramic x-ray, a periapical radiograph and cone beam CT were taken and shown as the images below. A lesion was identified as the arrows showed. (10 分)



What is your differential diagnosis?

接次頁

題號： 172

國立臺灣大學 108 學年度碩士班招生考試試題

科目： 口腔病理學

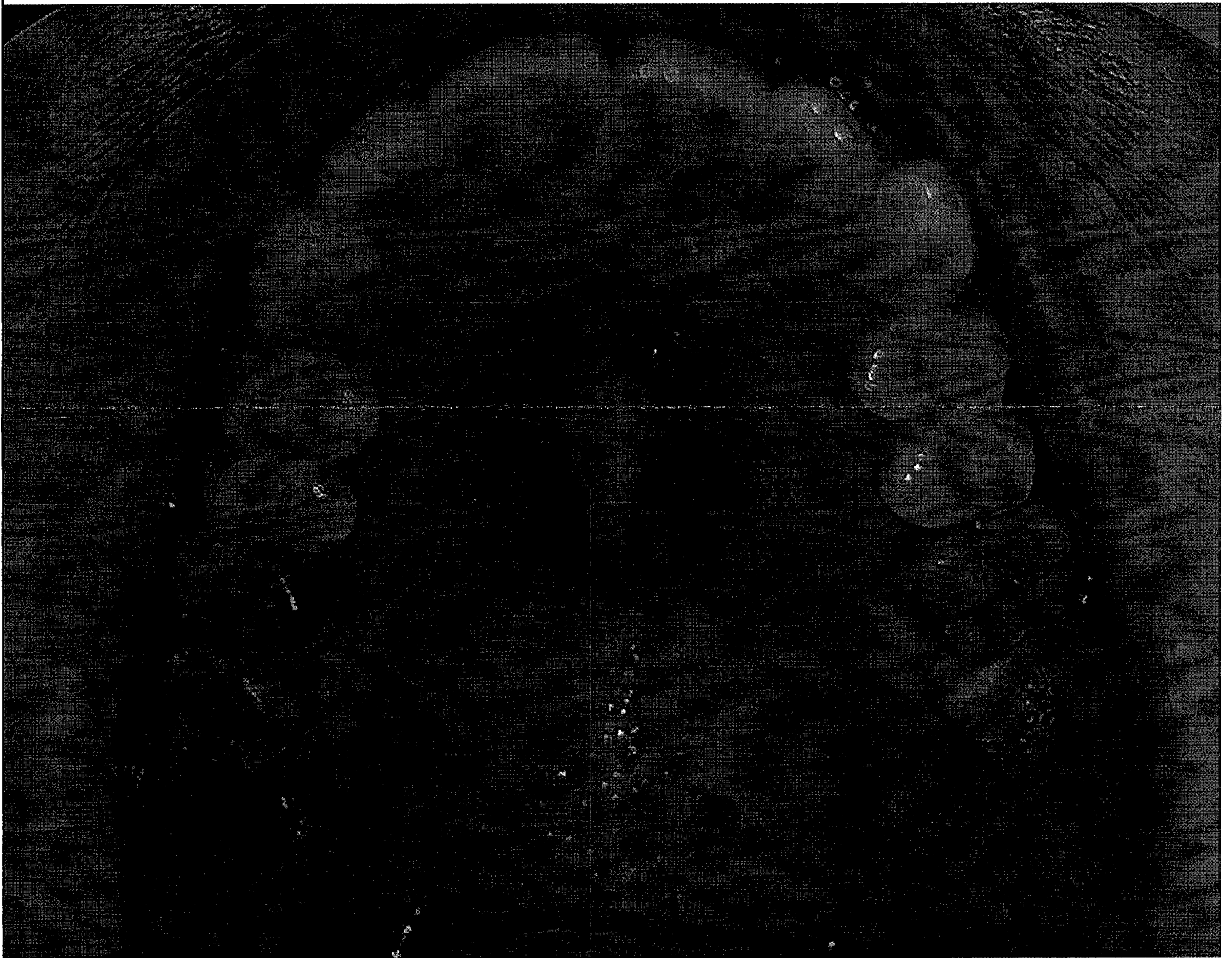
題號：172

節次： 2

共 8 頁之第 5 頁

How do you work up this case and what is your treatment plan?

7. A 45 year old female went to local dental clinic for regular dental check-up. A pigmented lesion was identified by the dentist, which was shown as the image below. Due to the concern of the lesion, the dentist referred the patient to you for further evaluation and treatment. (10 分)

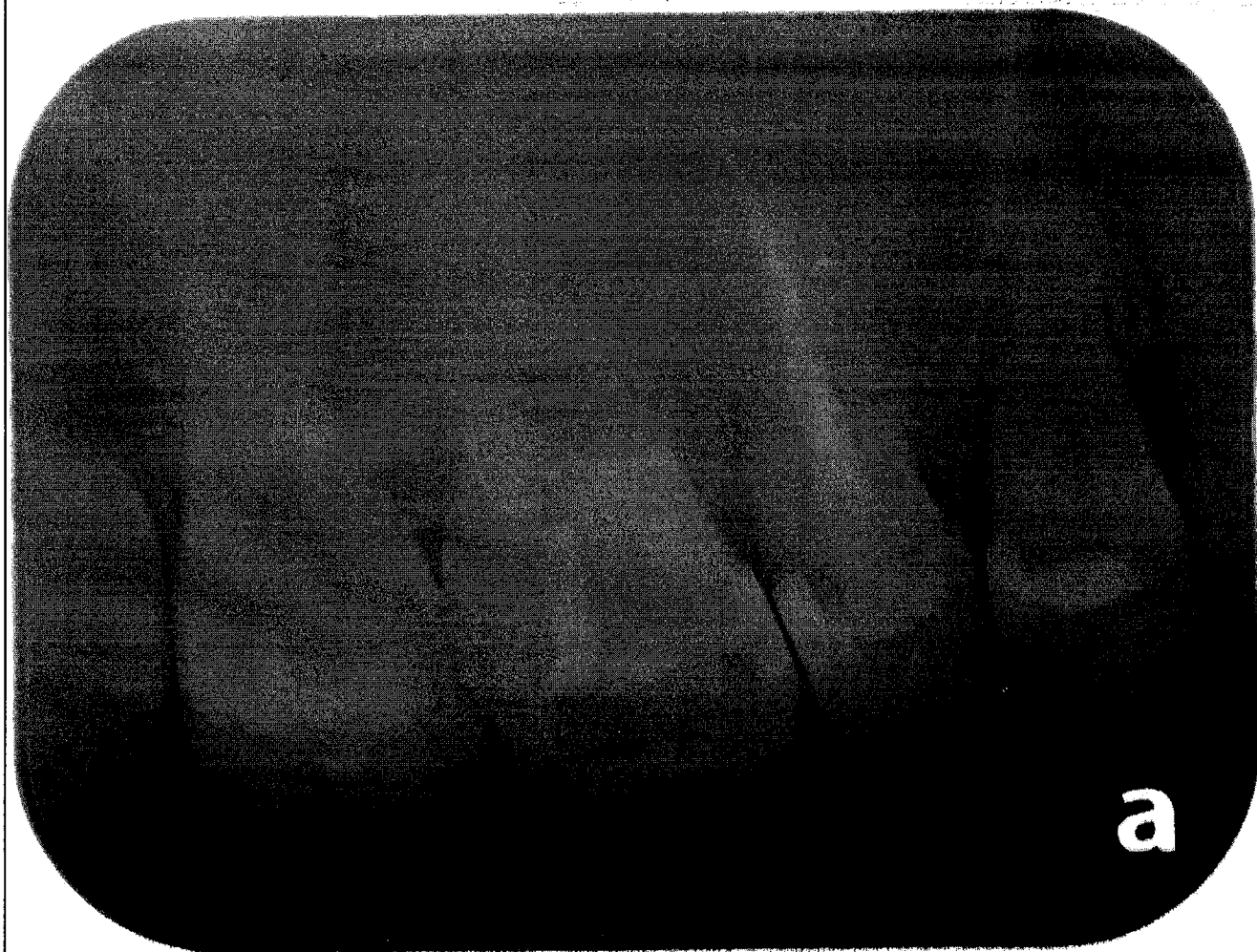
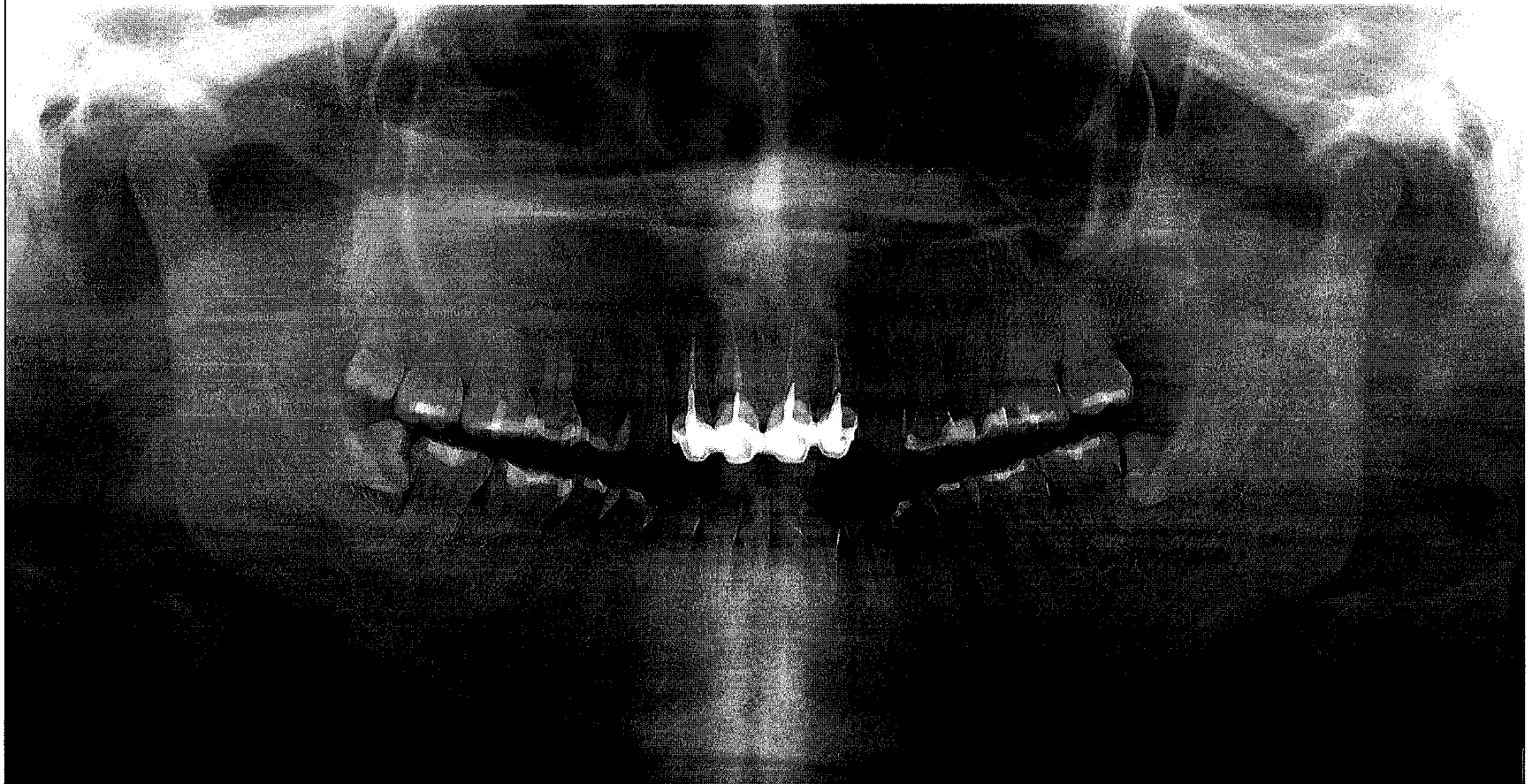


What is your differential diagnosis?

How do you work up this case and what is your treatment plan?

見背面

8. A 19 year old male complained of a slow growing swelling at right maxilla. A panoramic and periapical radiograph were taken and shown as the images below. (10 分)



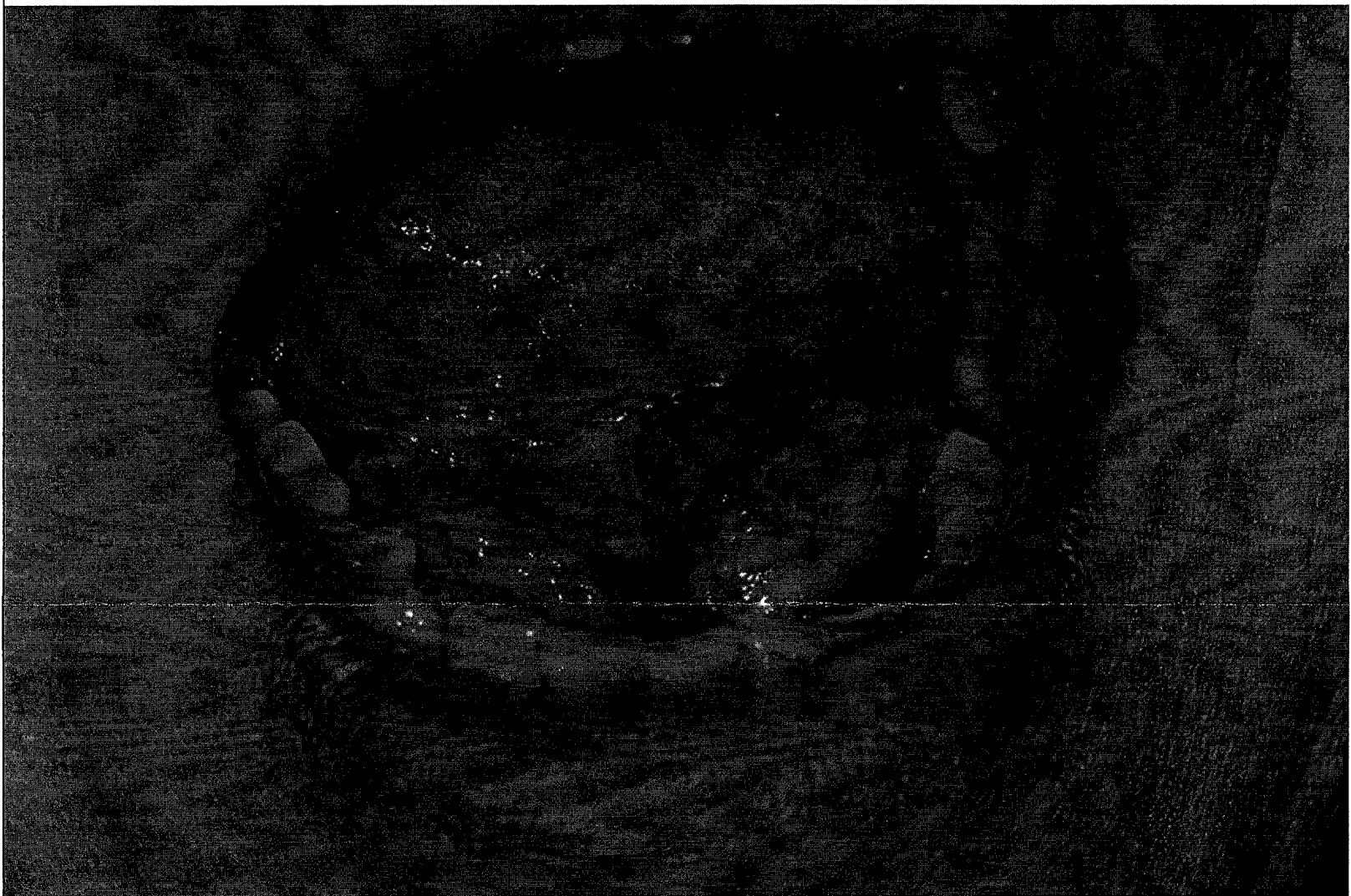
a

What is your differential diagnosis?

接次頁

How do you work up this case and what is your treatment plan?

9. A 64 year old male complained of a slow growing swelling at left side of floor of mouth for 1 year. The clinical picture of the lesion was shown below. (10 分)



Please describe the lesion.

What is your differential diagnosis?

How do you work up this case and what is your treatment plan?

10. Salivary gland neoplasms in different minor salivary gland locations show different prevalence as benign or malignant. Please describe the prevalence for benign or malignant or equal distribution of benign or malignant salivary gland neoplasm in the locations listed below: (10 分)

(1) Palate: _____

見背面

題號： 172
科目： 口腔病理學
節次： 2

國立臺灣大學 108 學年度碩士班招生考試試題

題號：172
共 8 頁之第 8 頁

- (2) Upper lip: _____
(3) Lower lip: _____
(4) Floor of mouth: _____
(5) Retromolar pad: _____

試題隨卷繳回