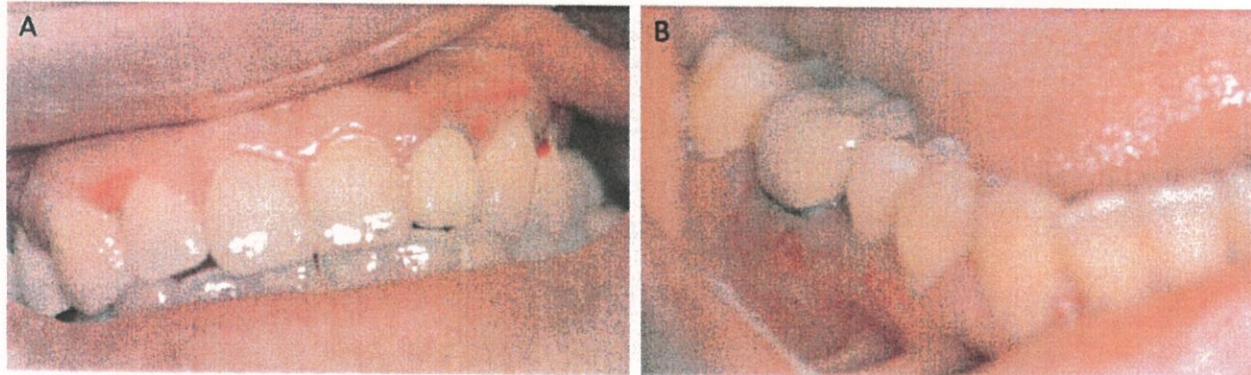
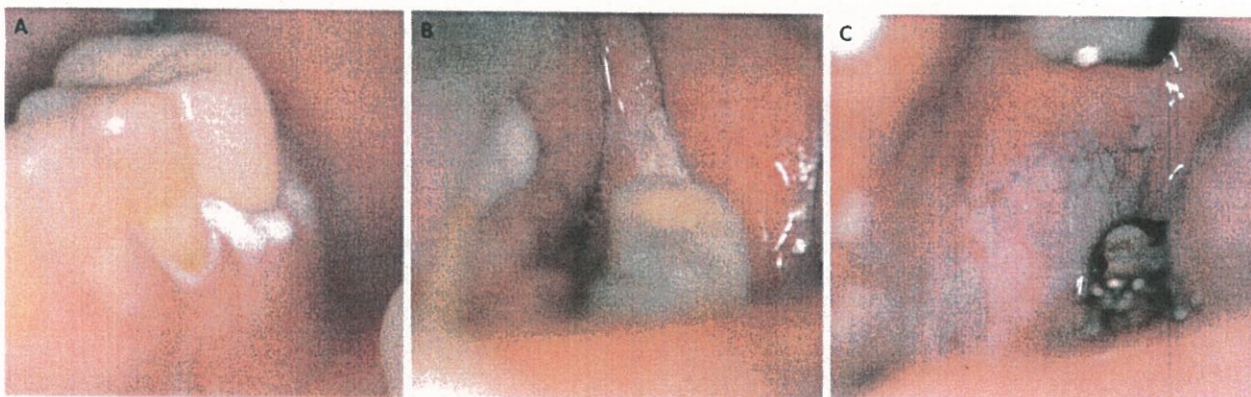


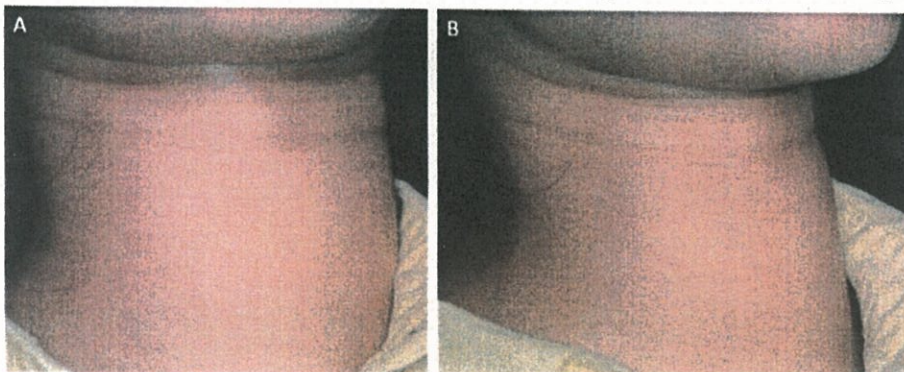
1. A 54 y/o female patient without alcohol, betel nut and cigarette smoking history. No known systemic diseases or currently used medication are noted. Patient complained of frequent vesicles and ulcerations after eating and brushing for 3 months. Based on the history and picture below, please describe (1) specific examination method; (2) differential diagnosis; (3) treatment plan; (4) possible pathologic findings based on differential diagnosis; (5) if biopsy will be performed, describe and mark where you will biopsy and your reason. (20 points)



2. A 67 y/o male patient complained of pain at tooth 37 extraction socket. Patient had smoking and betel nut chewing habits for 20 years and quit for 1 year. Patient stated the white lesion at tooth 36 cervical gingiva has been there for more than 1 year and slightly enlarging. Patient remembered the white lesion involved the tooth 37 before extraction. Tooth 37 has been extracted due to hypermobility 3 months ago. During examination, a white lesion was also noted in right buccal mucosa. Based on the picture below, please describe (1) any further examination; (2) differential diagnosis; (3) treatment plan; (4) possible pathologic findings based on differential diagnosis; (5) if biopsy will be performed, describe and mark where you will biopsy and your reason. (20 points)

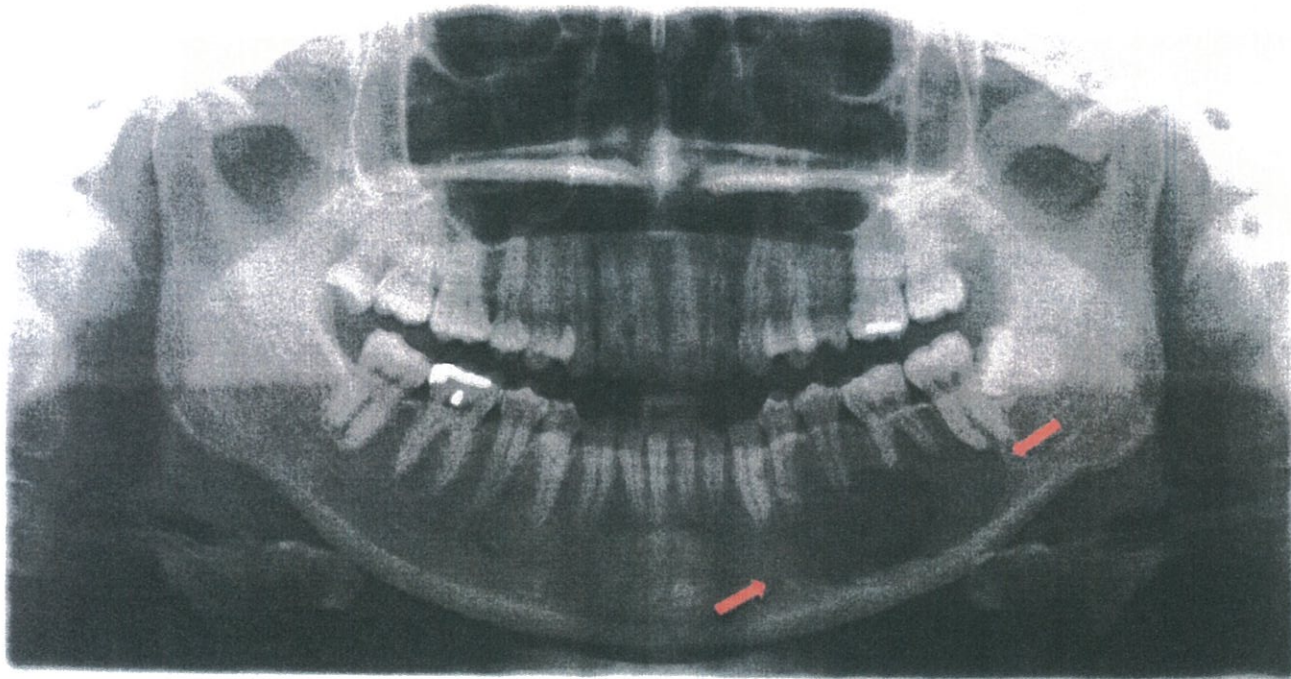


3. A 47 y/o female patient without alcohol, betel nut and cigarette smoking history. No known systemic diseases or currently used medication are noted. Patient complained of burning sensation of her tongue. No obvious abnormality in the oral cavity is identified. Patient seems to be slightly irritable. Based on the history and picture below, please describe (1) your findings; (2) differential diagnosis; (3) any further examination; (4) treatment plan; (5) what's the most serious problem might happen to this patient and how to management the patient if patient will receive dental treatment? (20 points)

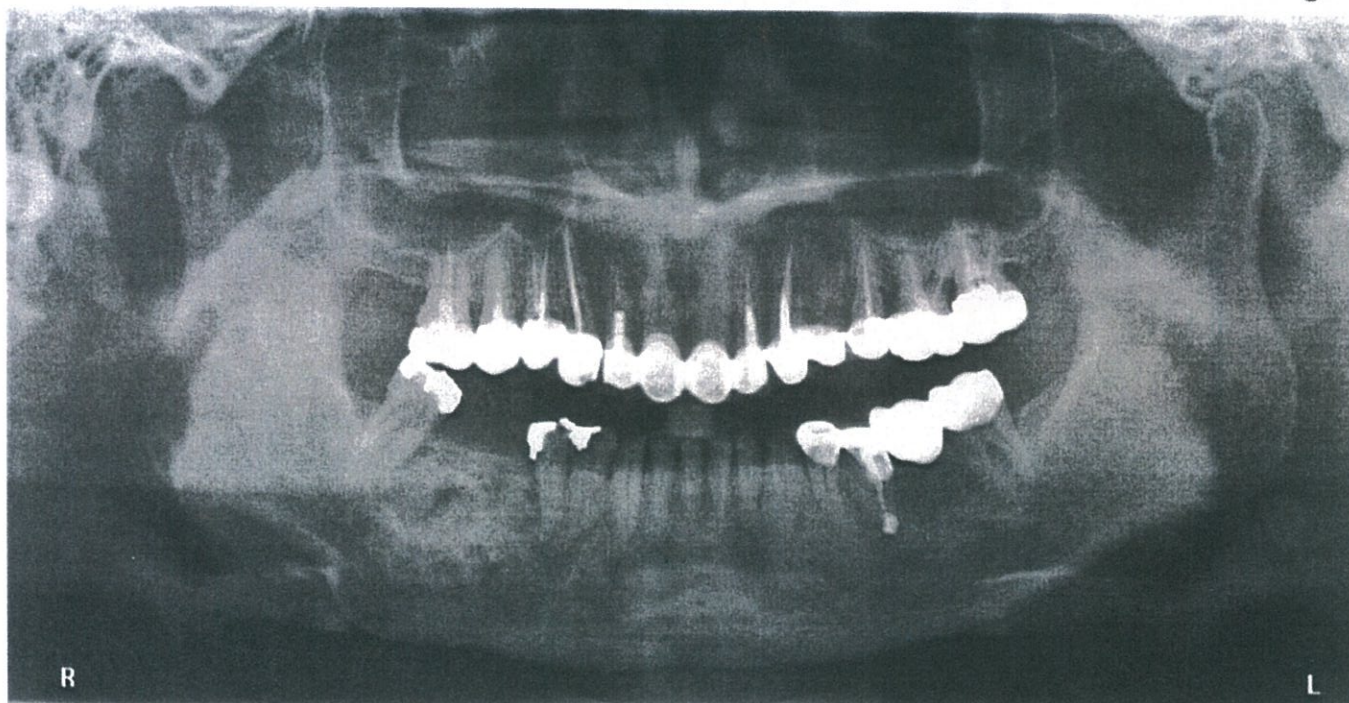


見背面

4. A 35 y/o male patient complained of slightly hypermobility of tooth 37 for 3 months and received panoramic x-ray examination. Based on the history and radiograph below, please describe (1) your findings; (2) differential diagnosis; (3) treatment plan; (4) possible pathologic findings based on differential diagnosis; (5) frequent genetic changes based on the differential diagnosis? (20 points)



5. A 37 y/o female patient complained of swelling at right side of mandible for 2 years and received panoramic x-ray examination. Based on the history and radiograph below, please describe (1) your findings; (2) any further examination; (3) differential diagnosis; (4) treatment plan; (5) possible pathologic findings based on differential diagnosis. (20 points)



試題隨卷繳回